



Tom Bereznicki

Rohit Patel and Megan Clark

Revisiting the Functionally Generated Path Technique: Is This an Aid to Predictable Digital Occlusal Design? Part 2. The Technique

Abstract: The precision of the occlusal scheme is paramount to the production of a successful fixed restoration(s) and its long-term success. The provision of the correct occlusal scheme is one of the requirements when working conformatively, whether in analogue or digital format. Part 1 highlighted occlusal schemes that provide difficulties using established techniques in arriving at a predictable restoration requiring minimal occlusal adjustments chairside. Part 2 introduces the theory of the functionally generated path (FGP) technique. Two cases involving implant-retained restorations are used to highlight the benefit of adopting this technique into the digital workflow in the provision of occlusally precise restorations.

CPD/Clinical Relevance: This article describes the value of the functionally generated path technique, when working digitally, for recording the occlusion for implant-retained restorations.

Dent Update 2022; 49: xxx-xxx

The authors show how marrying an old established technique with digital dentistry can provide an accurate occlusal scheme in cases where digital design alone may prove difficult, if not impossible. Many examples of these difficult occlusions and cases were outlined in Part 1 of this

series.¹ Although many of the steps here are shown in analogue form for clarity of presentation, most can also be delivered digitally: namely, scanning to give the definitive digital working model, design and fabrication of the milled titanium or zirconia abutment, printing the acrylic coping and

scanning the final design of the analogue functionally generated stent to mill the final restoration. Once mastered, the technique is very quick clinically, and its predictability more than makes up for the additional visit required to carry out the recordings, as the fit appointment becomes routine, and the frustration of occlusal adjustments is reduced.

The functionally generated path (FGP) technique

The original FGP technique is a method used to record the dynamic movement of the occlusal surface of teeth in one arch against wax (or a similar bite registration

Tom Bereznicki, BDS(Edin), MFDTEd, MFDSEng, MCGDent, Visiting Clinical Specialist Teacher, Department of Primary Dental Care, King's College London; Private Practice, Dawood & Tanner, Wimpole Street, London. **Rohit Patel**, BDS, MFDS RCS Ed, Clinical Tutor, Department of Restorative Dentistry, Queen Mary, University of London; General Practice, Brickfields Dental, Chelmsford. **Megan Clark**, BDS(Hons), BSc(Hons) AKC, Oral Surgery, Specialty Trainee, Newcastle. email: tom.bereznicki@kcl.ac.uk

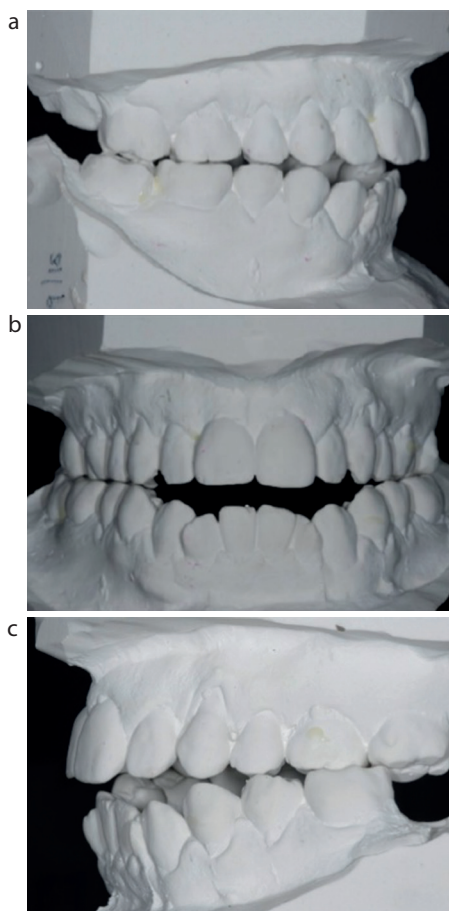


Figure 1. (a) Right buccal view in ICP showing occlusal contacts on only the first and second molars and second premolars. (b) Frontal view showing the anterior open bite in ICP. (c) Left buccal view showing contacts in ICP on the upper molars opposing the lower left first molar only.

material) on a recording base in the opposing arch. This can then be used as the definitive occlusal scheme for the final restoration. The main objective of using this approach is to minimize the need for occlusal adjustment at the fit stage as the dynamic movements of the mandible, and therefore these movements against the opposing cusps, have been recorded intra-orally on the plastic resin material at the bite registration stage. This tracing, made directly in the mouth, eliminates the requirement for an articulator that can reproduce these mandibular movements in the laboratory, whether working in analogue fashion with an articulator or allowing refinement of the occlusion during the design phase, if working with a digital workflow.

Meyer first described the FGP technique in 1933, elaborating on the technique in further detail in two later

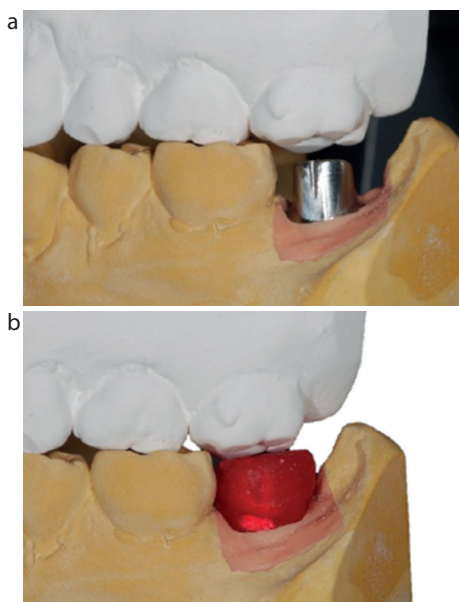


Figure 2. (a) Left buccal view of the milled custom titanium abutment showing adequate occlusal clearance. (b) Left buccal view of the fully seated acrylic resin coping.

articles for obtaining a balanced occlusion when designing both dentures and bridges.²⁻⁴ This technique has since been further refined and can be used to assist with the provision of conventional tooth and implant-supported crowns and/or bridges in cases with a difficult occlusion, as well as the provision of full dentures.

According to Dawson, and Shillingburg *et al*, there are certain prerequisites that must be met before carrying out the FGP technique.^{5,6} Some of these are as follows:

- Presence of an optimal occlusion;
- Elimination or absence of posterior interferences, unless anterior guidance is naturally absent. Using this technique as outlined in this article will allow many minor posterior interferences present to be accommodated conformatively rather than requiring their elimination by occlusal reshaping;
- Adequate opposing teeth: the occluding teeth present should be sound, non-carious with no deficient restorations and non-rotated, as the opposing occlusal pathway will not be present to sufficiently and accurately record the occlusal scheme for this technique.

This technique, which is also otherwise known as a 'cuspal tracing technique' or 'functional bite technique' has been adapted for use in computer-

aided design and computer-aided manufacturing (CAD-CAM).⁷

Method for a single implant-retained restoration in a case with a difficult occlusion

Patient Y presented in general practice having vertically fractured their lower left second molar, requiring extraction (Figure 1). Y had an anterior open bite (Figure 1b), with unfavourable minimal posterior occlusal contacts in maximal intercuspal position (ICP) on the second premolars, first molars and second molars on the right side (Figure 1a) and predominantly only on the first molars on the left side (Figure 1c). The lack of anterior guidance combined with the resultant guidance predominantly on the molars on both sides resulted in a score of 2 posteriorly on these teeth using the Smith and Knight tooth wear index.

Y was very keen to have this missing tooth replaced as he realized that it was one of the few teeth on that side that met prior to extraction and further appreciated that the resultant forces exerted on the remaining teeth were now correspondingly higher. He was aware that the lack of anterior guidance was, in all probability, the cause of the spontaneous fracture of his caries- and restoration-free lower second molar.

After a period of 3 months to allow for bony integration of the placed implant (Nobel Biocare UK, wide conical connection, wide platform 5.5 x 8.5 mm), the healing abutment was removed, and the implant torque tested to 35N to confirm bony integration. The requisite impression coping was fitted, and a conventional open tray impression taken using a polyether impression material (3M Impregum, St Paul, MN, USA). An impression of the opposing arch was taken in alginate along with conventional bite registration in Futar D (Kettenbach Dental, Eschenburg, Germany) to allow the technician to mount the working model against it. There was no expectation or necessity for this bite registration to be clinically accurate, merely accurate enough to allow the design of the milled abutment to have adequate clearance for the new final restoration from the opposing tooth.

In the laboratory, the working model was mounted against the upper arch model on a semi-adjustable articulator using the bite registration. A facebow

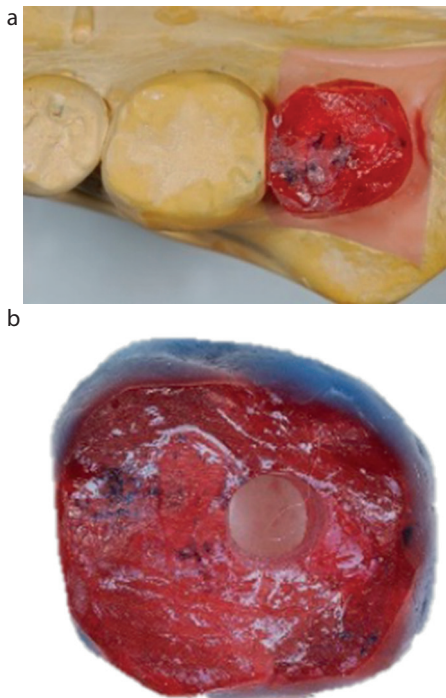


Figure 3. (a) Occlusal view of the coping re-seated on the abutment on the model once the patient had reproduced the full range of mandibular excursive movements. **(b)** Occlusal view of the coping following refinement of the access cavity incorporation.

recording was not required because the occlusion was recorded later with the FGP technique. The recorded bite enabled the laboratory construction of a milled custom titanium Procera abutment (Nobel Biocare UK; Figure 2a), with adequate clearance of 2–3 mm occlusally. This allowed a well-fitting rigid acrylic resin coping to be formed in auto polymerizing acrylic (Pattern Resin LS, GC Corporation, Tokyo, Japan). As this coping (Figure 2b) provides the recording base for the FGP registration, it is essential that it has an accurate fit on the implant abutment, be stable and fully seated, as well as ensuring there are no contacts with the opposing teeth in ICP or in any mandibular excursions. The contact point, at this stage, should be left shy of the adjacent tooth to allow for full seating intra-orally.

On a subsequent appointment, the healing abutment was removed, and the gingival tissues and the implant head gently cleaned with a soft brush dipped in chlorhexidine. The abutment was then fitted to the recommended torque, in this case 35N. The coping was then trial fitted and checked to ensure an absence of contacts in ICP and mandibular excursive

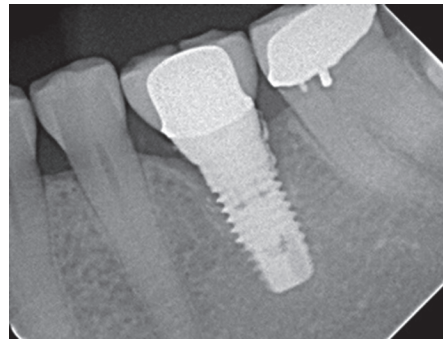


Figure 4. Radiograph showing retained cement on the distal surface of the implant and associated bone loss. The excess cement was later removed under an open flap procedure.

movements as outlined earlier, and further adjusted if necessary. A thin layer of Vaseline was then applied to the occlusal surfaces of the teeth opposing the coping to ensure that the pattern resin used during the bite registration phase would not stick to them. The coping was refitted onto the abutment and a sludgy mix of pattern resin applied over the occlusal surface in a layer that was thick enough for the opposing molars to touch. The patient was then asked to bring their teeth together followed by conducting their full range of mandibular excursive movements – left lateral, right lateral and protrusion, along with a return to ICP, and encouraged to continue to do so until the pattern resin had set.

Once set, the coping was removed and the occlusal surface studied. Had any voids had been present, the coping would have been re-seated, and a thin layer of resin re-applied only in the area of the voids and the patient asked to once again reproduce the various mandibular excursive movements. The coping was then removed and any excess acrylic beyond the occlusal table trimmed away, with special attention being paid to ensure that the proximal contact was not heavy which, in turn, could prevent the coping re-seating accurately on the abutment on the model.

The coping was then re-seated on the abutment intra-orally, and the occlusion checked to ensure that the contact with the opposing tooth not only held shimstock in ICP, but also on the other teeth that had been previously recorded as having occlusal contacts in ICP around the arch. Adjustments to the coping were made accordingly where required. It is, however, very rarely necessary to adjust the occlusion on the coping if this technique is carried out correctly.

The coping and the abutment were then removed from the mouth and re-seated on the model, ensuring that the coping at this stage did not contact the adjacent tooth and was fully seated (Figure 3a).

Following standard cross infection protocols, the models, abutment and coping were returned to the laboratory for the technician to finalize the final crown contours and contact points in wax. There is no need to remount the models on an articulator as the occlusal scheme has already been refined. It is imperative that further changes to the generated occlusal pattern are not made, other than minor subtractive changes to create some fissure morphology if required. If an access cavity is being incorporated into the design, the technician refines it at this point (Figure 3b).

Screw- or cement-retained restorations

Retained subgingival cement is often the cause of future implant failure as shown in Figure 4.⁸ If the crown is designed without an access cavity and cemented conventionally intra-orally, there is every chance that any excess cement extruded at or below the fit margin may prove difficult or, occasionally, impossible to remove.

The authors prefer the design of implant-retained crowns/bridges to include an access cavity through to the underlying abutment screw to allow removal of excess cement at the time of final fit of the crown. This design also allows retrievability should it loosen with time and function. Once the abutment and associated definitive restoration have been trial fitted and any occlusal adjustments required carried out, final cementation of the crown to the abutment occurs on the model. The access cavity in the abutment should be filled with PTFE tape to ensure that the luting cement does not inadvertently fill it, blocking off access to the screw head. This technique also allows total removal of any excess cement and polishing the margins prior to final fit. Once the final fit is completed, the access cavity is again filled with PTFE to within 4 mm of the occlusal surface followed by a matching shade of composite resin.

Choice of materials

The next step depends on the final restoration choice, namely milled, gold or metal–ceramic materials.

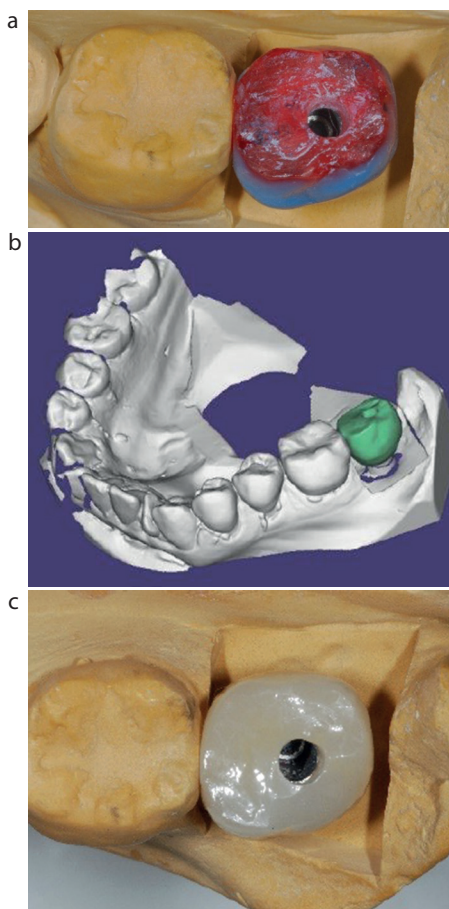


Figure 5. (a) Occlusal view of the coping waxed to full contour prior to scanning. (b) Once waxed to full contour, the coping is scanned. (c) The milled and sintered restoration ready for trial fit.

Milled zirconia

The coping, once waxed to full contour (Figure 5a), is digitally scanned (Figure 5b) following normal protocols, milled and sintered ready for trial fit (Figure 5c).

As aesthetics were not an issue in this case, 3Y zirconia was chosen for its strength. 4, 5 and 7Y zirconia were not considered as the increase of yttrium content, although improving the translucency and aesthetics, reduces the flexural strength, increasing the susceptibility to fracture.⁹ The option of a printed gold crown could be an alternative digital restoration, but the cost of these restorations currently precludes their provision for most patients.

Milled lithium disilicate

The flexural strength of milled lithium disilicate restorations is reported as being between 370mPa and 450mPa, which is significantly lower than that of milled 3Y zirconia. So, although the aesthetics of lithium disilicate are vastly superior, it is

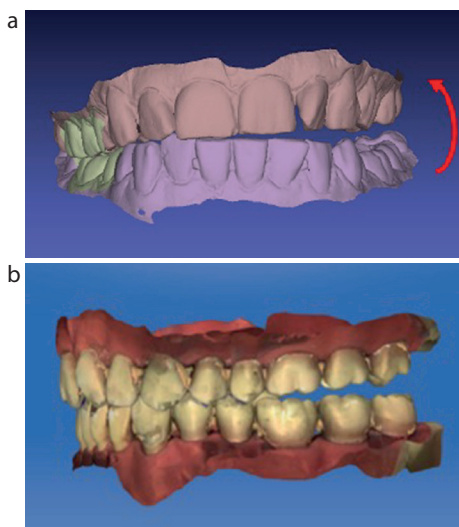


Figure 6. (a, b) Simulation photographs showing a common discrepancy in full arch scanning. Photos courtesy of Andrew Keeling, Leeds.

not the material of choice for use in heavy occlusal stress situations such as those featured in this article.⁹

Cast gold

This material is probably the best choice for this type of restoration as its property of malleability is ideal, meaning the material continues to conform to the changing guidance as wear of the remaining teeth occurs with time. If gold is the final restoration of choice, the final wax up is simply sprued, invested and cast following normal lost wax technique protocols. Again, the choice must be made as to whether to include an access cavity in the design.

Porcelain fused to metal (PFM) restorations

This option is not recommended in any situation where anterior guidance is absent because the feldspathic porcelain used to cover the metal substructure is prone to fracture in high-stress situations. Similarly, milled 3Y zirconia cores layered with feldspathic porcelain should be avoided as studies show an even higher rate of porcelain delamination under loading than that encountered with PFM restorations.¹⁰ Should PFM be the preferred design for the restoration, certain other additional steps need to be undertaken, details of which are dealt with later in this article.

The final trial fit of the milled abutment and zirconia restoration in this featured case was carried out with only minimal adjustment required in either ICP or any of the mandibular excursions. Any adjustments,

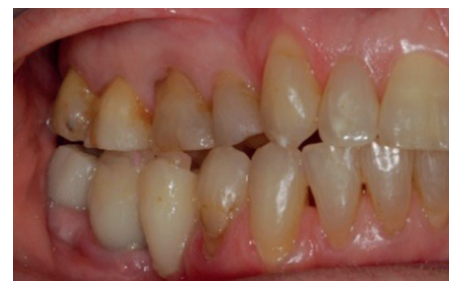

Figure 7. Right buccal view. An example of a provisional milled hybrid porcelain bridge on fitting in severe infra-occlusion.

where required, were polished. The 'soft tissue' was removed from the working model and after removal of the abutment from the implant, fitted onto the replica. The access cavity was filled with PTFE tape, and the crown cemented with resin-modified glass ionomer cement (Fuji Plus, GC Corporation, Tokyo, Japan). Once set, the excess cement was removed from the crown/abutment interface and any residual cement polished away. The PTFE tape was removed, and the crown/abutment assembly fitted intra-orally in a conventional fashion, torqued to 35N, the access cavity filled with PTFE tape to within 4 mm of the occlusal surface and then filled with composite. In this case, a dentine shade of Venus Pearl (Kulzer GmbH, Basingstoke, UK) was used to fill the remainder of the access cavity. The authors find that the filling in the cavity is generally less obvious if a dentine shade is used. The filling was shaped, light cured, occlusion checked and polished as necessary.

Use of the FGP technique in cases requiring cross arch scanning with digital workflow

In Part 1 of this article series, the issues and problems involved with the accuracy of occlusal recordings involved in cross arch scanning were dealt with in detail.

The diagrammatic screen shots in Figure 6 clearly show one of the occlusal discrepancies that can occur, and provide an explanation for clinical findings where the milled restorations provided can be correct, or in either infra- or supra-occlusion.

In a separate case, Figure 7 shows a digitally scanned and designed provisional milled hybrid porcelain bridge on fitting in severe infra-occlusion. The authors decided to add composite to the occlusal surfaces of the second premolar and first molar, as

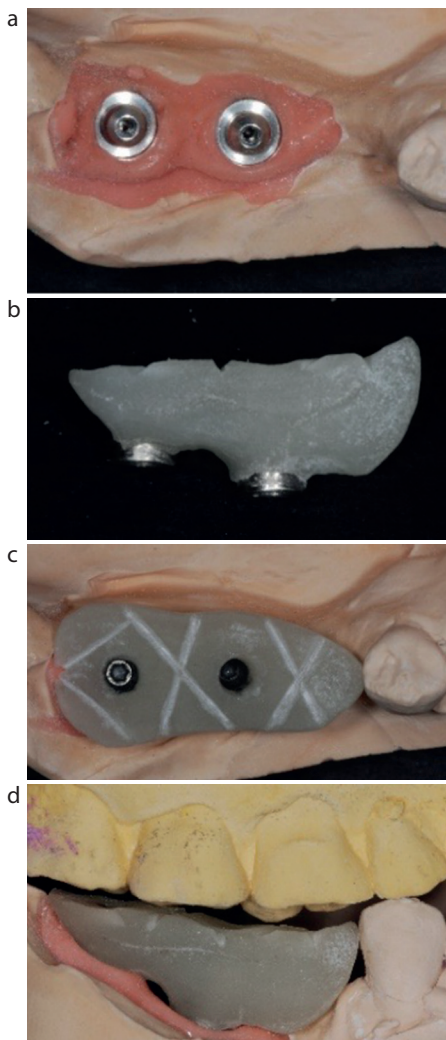


Figure 8. (a) Occlusal view of the implant replicas on the analogue working model. (b) Buccal view of the recording jig. (c) Occlusal view of the jig screwed into place on the working model. (d) Adequate occlusal clearance from the opposing dentition.

shown in Figure 7, to bring the bridge into supportive occlusion while a replacement was constructed. As there was no guarantee that re-scanning the case would provide a restoration with the correct occlusal scheme, the decision was taken to adapt the FGP technique described previously to see whether a definitive milled restoration with the correct occlusal scheme could be predictably provided.

The multi-unit wide platform abutments (Nobel Biocare, UK) on the working model of the same case are shown after implant placement and working in analogue fashion following a conventional impression (Figure 8a). Figure 8b shows the screw-retained acrylic jig fabricated to act as a base for

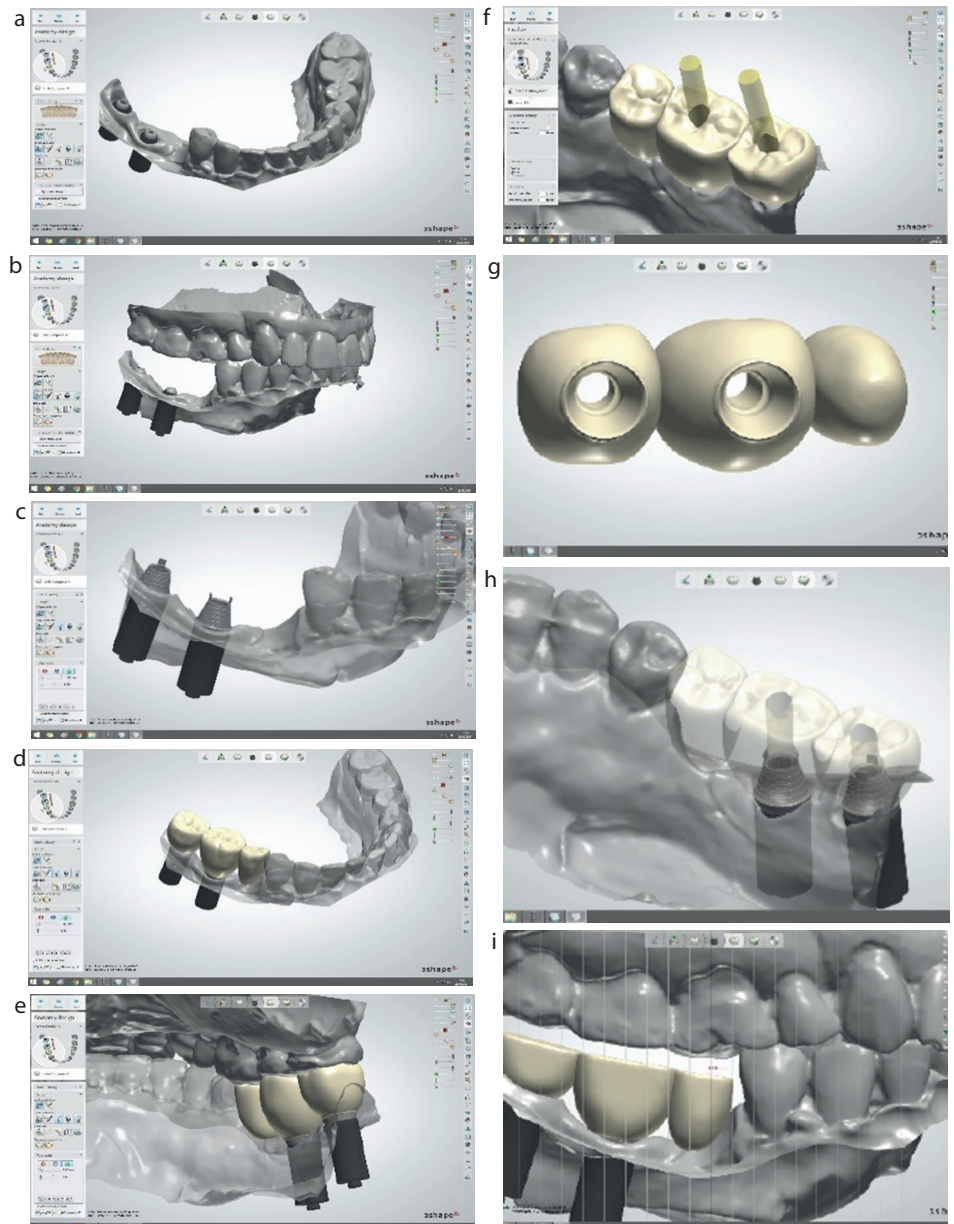


Figure 9. (a) Buccal view of scanned lower arch and implants fitted with multiunit abutments. (b) Buccal view of the scanned upper and lower arches in provisional ICP. (c) Buccal view of the implants with temporary cylinders fitted onto multi-unit copings. (d) Buccal view of the initial design of a three-unit bridge to be adapted to become a recording jig. (e) Lingual view of the same bridge. (f) Occlusal view of the bridge following design of the access cavities. (g) View of the fit surface of the proposed jig. (h) Occlusal view of the final design prior to adaptation of the occlusal surface to create the jig. (i) Lingual view of the designed jig with adequate occlusal clearance and ready for milling in composite.

the FGP technique – the grooves are to ensure adequate mechanical retention for the registered FGP pattern. Figure 8c shows the jig screwed onto the multi-unit implant heads. The analogue jig should have a minimum of 2 mm of occlusal clearance from the opposing dentition as shown in Figure 8d, as well as being wider than the proposed occlusal scheme in order to support the GC Pattern Resin.

If working in digital format, conventional implant scanning would be employed to produce the virtual model, the stent designed and then milled. The digital design, along with a description of the various stages involved, are shown as a sequence (Figure 9).

The jig produced digitally should look almost identical to the jig shown in Figure 8, but mimicking the shape of the

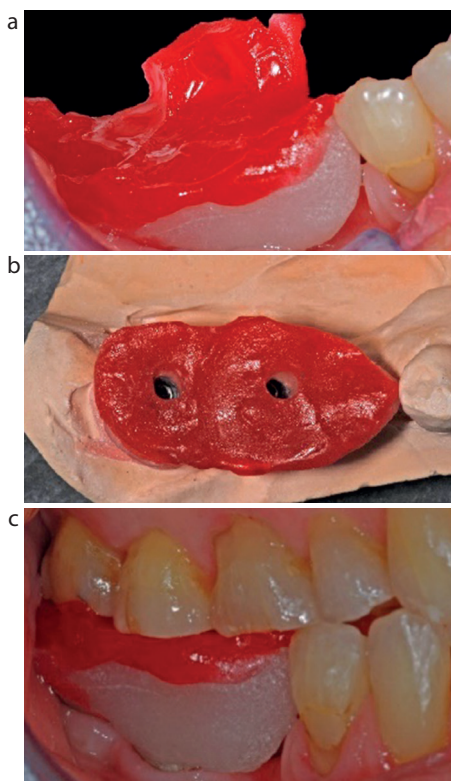


Figure 10. (a) Right buccal intraoral view of the jig and the occlusal pathways generated in the resin. (b) Occlusal view of the jig located on the analogue working model following initial trimming of the excess acrylic and the access cavities revealed. (c) Right buccal view of the jig refitted intra-orally to allow the occlusion to be checked once some refinement of the occlusal width had been carried out chairside.

future bridge as shown in Figure 9i. The required locating/retention grooves can be cut chairside prior to the next step in the technique.

Whether working with the analogue or digital jig, the clinical sequence would be the same, namely to fit the jig intra-orally and torque to 15N, with the access cavities filled with PTFE tape to avoid inadvertently filling them with GC Pattern Resin during generation of the FGP. This, in turn, allows easy location of these cavities once the resin has set, giving easy access for the driver to unscrew and remove the jig. A thin layer of Vaseline was smeared on the occlusal surfaces of the opposing teeth, and the resin placed on the jig, as described previously in this article.

The authors have chosen to show the next clinical steps using the analogue jig and working model to ensure the desired outcome is easier to follow. Figure 10a shows the initial occlusal morphology created with the technique prior to

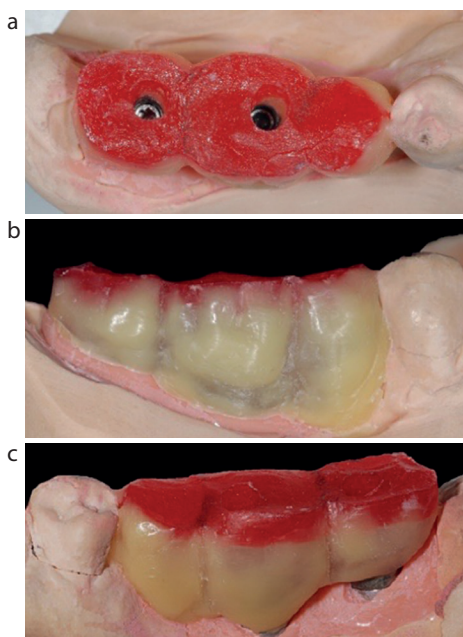


Figure 11. (a) Occlusal view of the finalized occlusal contours on the working model. (b) Buccal view following final additions of wax to define the contours. (c) Lingual view.

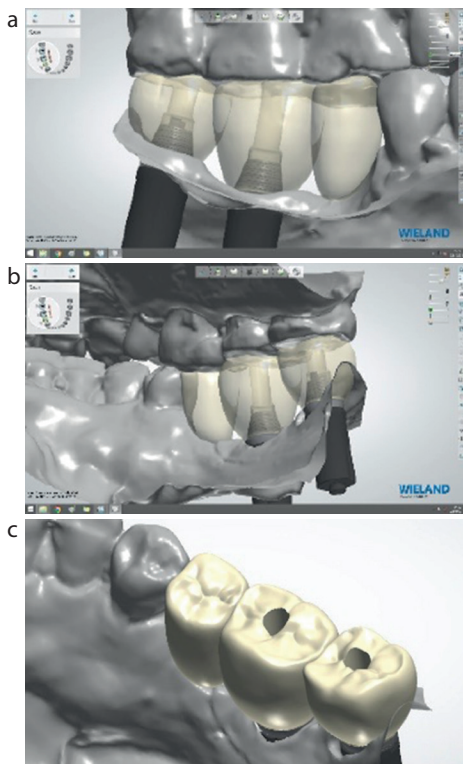


Figure 12. (a) Right buccal view of the scanned bridge on the virtual model. (b) Right lingual view of the scanned bridge on the virtual model. (c) Occlusal view of the scanned bridge.

revealing the access cavities and removal of the jig from the mouth. Figure 10b shows the jig refitted on the working model with the generated occlusal morphology

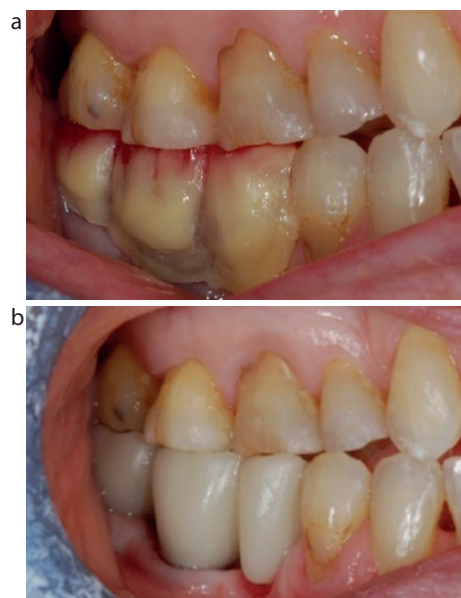


Figure 13. (a) Right buccal view of the laboratory finalized wax/acrylic bridge in situ showing the occlusion maintained. (b) Right buccal view of the fitted milled acrylic bridge showing identical predictable occlusal contacts achieved with the jig and requiring almost no adjustment.

clearly visible following location of the access cavities and trimming excess acrylic. Figure 10c shows the jig refitted intra-orally after further refinement of the occlusal width. At this stage, shimstock should be used to check that the remaining natural teeth are in occlusion in ICP, and if not, the acrylic is simply trimmed away, and the process repeated.

Figure 11 shows the jig fitted on the model and the contours built up in wax in the laboratory. Adjustments to the occlusal morphology are best avoided, but should some additional characterization of the occlusal surface be required, then this can be carried out at this stage if the changes are mildly subtractive, for example to enhance the fissures. Additions should not be made under any circumstances. The finalized jig is now ready for scanning.

When working in digital format, the excess Pattern Resin on the jig is trimmed away and shaped in the laboratory prior to scanning. The scan shown in Figure 12a clearly shows the demarcation between the jig and the new occlusal surface and, along with Figures 12b and c, shows the results following scanning, along with minor final adjustment of the buccal contours. Once this stage has been carried out, the milling of the restoration is carried out in conventional fashion in the material of choice.

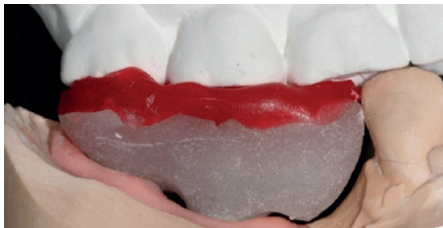

Figure 14. Right buccal view of the existing upper model articulated against the jig in ICP.

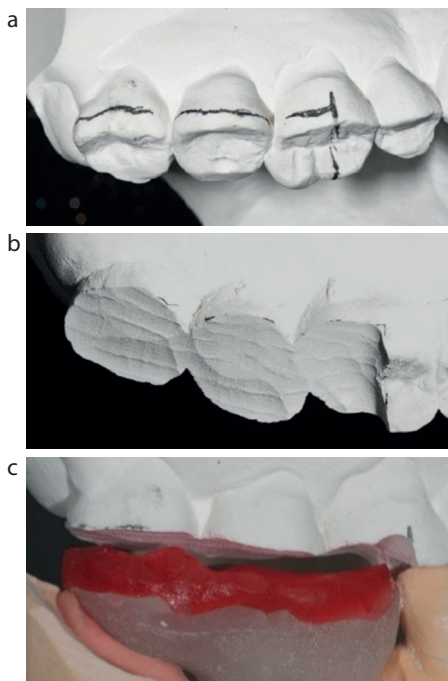


Figure 15. (a) Shows the planned reduction of the upper model opposing the jig. (b) Shows the upper model after trimming. (c) Shows the degree of reduction required in the upper model.

Figure 13a, for illustrative purposes in this article, shows the fully contoured wax bridge with the original occlusal morphology repositioned in the mouth showing the same occlusal contacts maintained in ICP on the remaining teeth. The authors were of the opinion that, taking into consideration the second premolar in the bridge involved a cantilever, milled zirconia was not the ideal material of choice for the final restoration as there was the possibility of the pontic fracturing off the framework during function. The bridge shown in Figure 13b was milled solely in acrylic for this article and fitted temporarily to show the predictable result that can be achieved with the occlusion using the digital technique presented in this article. Almost no adjustments were required to the occlusal surface in ICP or mandibular excursions, demonstrating just how

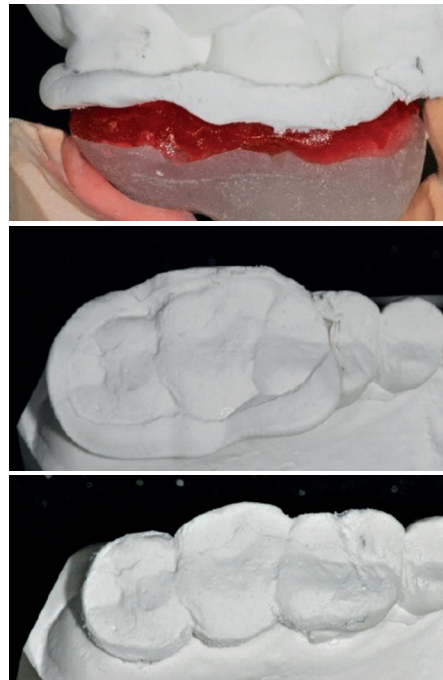

Figure 16. (a) Right buccal view after fresh plaster was added to the upper model and allowed to set. (b) Occlusal view of the new occlusal morphology which now mirrors the occlusal scheme of the jig. (c) Occlusal view of the new opposing model after trimming excess.

predictable this technique is. Had the bridge been constructed in zirconia, there is no reason to believe that the resultant occlusal morphology and correct occlusion would have been significantly different from the acrylic one.

As discussed earlier, as the bridge design included a cantilever, the material of choice for this patient was a conventional screw-retained implant bridge fabricated in PFM. The choice of this material involves a few additional laboratory steps. It is crucial that the occlusal morphology created by using the FGP technique is reproduced in porcelain. Therefore, the original opposing model cannot be used to reproduce the occlusal scheme created by the jig. As a first step, the lower model, along with the jig *in situ*, can be used to articulate the original working upper model in ICP, as shown in Figure 14.

However, as the current occlusal scheme of this upper model cannot reproduce all the excursive movements recorded in GC Pattern Resin, the upper model needs to be adapted to give a 'negative' surface of the desired occlusal scheme, which can then be used as a 'stamp' when building up the occlusal surface of the bridge in feldspathic porcelain. To achieve this, the occlusal surface of the

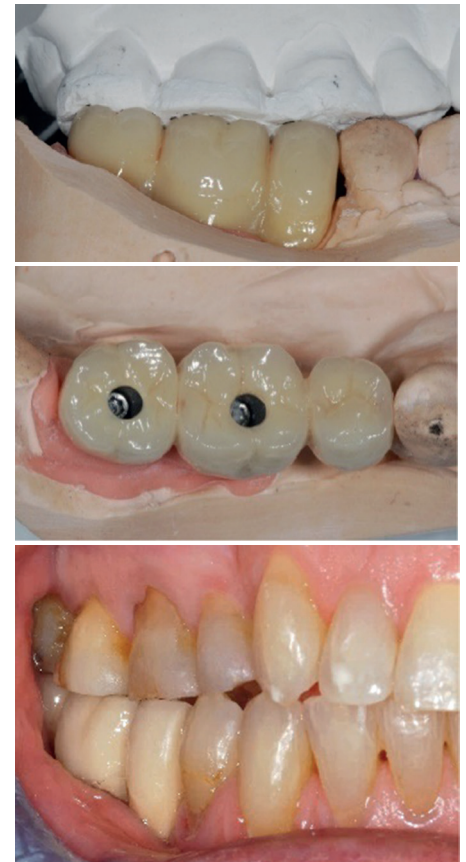


Figure 17. (a) Right buccal view of the final PFM bridge articulated against the adapted upper model. (b) Occlusal view showing the definitive PFM bridge on the working model. (c) Right buccal view showing the PFM bridge after final fit.

upper model opposing the jig needs to be cut away as shown in Figure 15a and b. It is important to ensure there is adequate reduction of the plaster of the upper model in this area to allow at least 4–5 mm of new plaster to be added.

The technician then adds plaster to the opposing model and articulates the mounted models against each other until the plaster has set, as seen in Figure 16a. Figure 16b shows the new occlusal surface of the opposing teeth along with the excess plaster. Figure 16c shows the newly created opposing model with the excess trimmed away.

This 'stamp' is used to accurately reproduce, in feldspathic porcelain, the same occlusal scheme that was originally created with the FGP technique in resin on the jig.

Figure 17a shows the final bridge, after glazing, articulated against the adapted opposing model. Figure 17b shows the detailed occlusal morphology achieved, and in Figure 17c, the bridge has been fitted. No

occlusal adjustments were required, and the occlusal contacts were such that shimstock held on all the teeth around the arch.

Observations

The FGP technique shown can be used to produce a predictable occlusal scheme in the final restoration if working in digital format, which in turn requires no, or only the most minimal, final adjustments to milled crowns and bridges whether tooth supported, or implant retained. This is a very satisfying outcome, avoiding time-consuming and frustrating adjustments to restorations, particularly if zirconia is the chosen material. The FGP technique can also be easily transferred, with some adaptation as outlined, to those analogue cases, whether tooth or implant supported, that have difficult occlusions and the material of choice of the final restoration(s) will not involve milling.

The use of the FGP technique to design the occlusion, as shown in this article, is more accurate when compared to either analogue or digital articulation and occlusal planning, and is much easier and more predictable, particularly with complex occlusal schemes.

Discussion

Although an extra appointment is required for the FGP recording, there are several advantages to using this technique over conventional methods of bite registration, including potentially negating the time taken with requirements for facebow recordings and the need for very accurate intra-oral bite registrations. It is simple and reliable, and decreases the need for multiple repeated adjustments at the fit stage, therefore keeping the design of the occlusal morphology of the final restoration, particularly if the restoration is to be constructed in zirconia.^{7,11,12}

However, as with any technique, there are also disadvantages to the functionally generated pathway approach. This includes technique sensitivity: the operator should have a good understanding of occlusion and mandibular movements in order to generate the movements required from patients when recording, along with good useful laboratory support.^{7,12}

Contraindications to using this technique include patients who suffer from temporomandibular joint dysfunction, or neuromuscular problems that may hinder proper assessment and recording

of the functional path, along with those patients with severe tooth wear, tooth mobility of the opposing teeth and severe malocclusion.^{7,12} It is also a technique that cannot be used predictably in those patients who find it difficult to carry out mandibular excursions.

Conclusion

The use of this technique produces a static representation of the dynamic occlusion in excursive and lateral contacts, providing a bite registration that, if carried out carefully, can result in a final restoration that requires minimal chairside adjustment – this being a major advantage over conventional techniques when working with a digital flow. The technique shown is relatively simple and straightforward to use and does not require any specialized equipment or training, merely attention to detail. However, long-term multi-centre clinical trials are required to assess and compare the presumed accuracy of the technique to more conventional digital design techniques.

Compliance with Ethical Standards

Conflict of Interest: The authors declare that they have no conflict of interest.

Informed Consent: Informed consent was obtained from all individual participants included in the article.

Acknowledgements

We also gratefully acknowledge Steve Ridgewell at Fulcher & Ridgewell, London, for his laboratory support in casting and supplying models and final restorations for these cases, and Terry Quince, digital technician at Dawood & Tanner, London, for his work on the cases presented.

References

1. Bereznicki T, Patel R, Clark M. Revisiting the functionally generated path technique: is this an aid to predictable digital occlusal design? Part 1: introduction and background. *Dent Update* 2022; **49**: 371–378.
2. Meyer FS. A new, simple and accurate technique for obtaining balanced and functional occlusion. *J Am Dent Assoc* 1934; **21**: 195–203.
3. Meyer FS. The generated path technique in reconstruction dentistry: part I. Complete dentures. *J Prosthet Dent* 1959; **9**: 354–366.
4. Meyer FS. The generated path technique in reconstruction dentistry: part II. Fixed partial dentures. *J Prosthet Dent* 1959; **9**: 432–440.

5. Dawson PE. *Evaluation, Diagnosis and Treatment of Occlusal Problems*. 2nd edn. St Louis, MO, USA: CV Mosby; 1989, 410–433.
6. Shillingburg HT, Hobo S, Whitsett LD *et al*. *Fundamentals of Fixed Prosthodontics*. 3rd edn. Chicago, IL, USA: Quintessence; 1997, 355–364.
7. Saafi J, Debbabi I, Alremthi HA *et al*. A modified functionally generated path technique (FGP) for making posterior unit metal-ceramic crown: a case report. *J Oral Dent Sci* 2018; **2**: 103.
8. Dawood A, Marti BM, Tanner S. Peri-implantitis and the prosthodontist. *Br Dent J* 2017; **223**: 325–332. <https://doi.org/10.1038/sj.bdj.2017.755>
9. Zarone F, Di Mauro MI, Ausiello P *et al*. Current status on lithium disilicate and zirconia: a narrative review. *BMC Oral Health* 2019; **19**: 134. <https://doi.org/10.1186/s12903-019-0838-x>
10. Upadhyay SR, Singh SV, Bhalla G *et al*. Modified functionally generated path technique for single complete denture against non-modified natural dentition. *J Oral Biol Craniofac Res* 2012; **2**: 67–71. [https://doi.org/10.1016/S2212-4268\(12\)60016-5](https://doi.org/10.1016/S2212-4268(12)60016-5)
12. Prashanti E, Sajjan S, Reddy JM. Fabrication of fixed partial dentures using functionally generated path technique and double casting. *Indian J Dent Res* 2009; **20**: 492–495. <https://doi.org/10.4103/0970-9290.59453>