

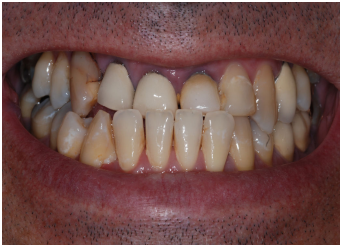Edentulous Solutions – Mild Bone Resorption

Individualized restorations - The perfect solution for the esthetically compromised patient

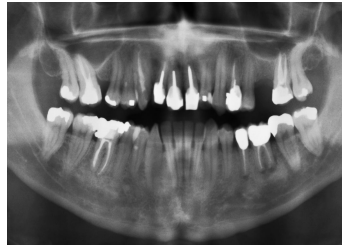Patient: 48-year old male patient presented with several painful and highly compromised teeth in both jaws. **Overall Health:** No systemic diseases.

Chief complaint: Poor appearance of teeth and an awareness of the reversed jaw relationship – had contemplated orthognathic surgery previously.

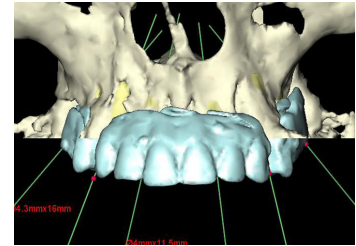
Oral Examination: The upper lip was fairly short. A panoramic radiograph showed several extensively restored and highly compromised teeth in both jaws. In the maxilla, a mild bone resorption pattern with the restoration of the remaining teeth would have complicated the treatment. In the mandible, most of the lower teeth were restorable with excellent bone levels. **Decision:** In the maxilla, most of the upper teeth were extracted. The implants were placed immediately into the extraction sockets and a removable provisional prosthesis was provided to the patient. As a final solution, a full maxillary reconstruction with NobelActive implants in combination with a precision milled fixed NobelProcera Implant Bridge Titanium, for improved esthetics, strength and correction of occlusal relationship was decided. In the mandible, individual replacement of the highly compromised teeth with NobelProcera Crowns Zirconia cemented to individualized NobelProcera Abutments Titanium on NobelReplace Straight Groovy implants was the treatment of choice **Time for total treatment:** 9 months.



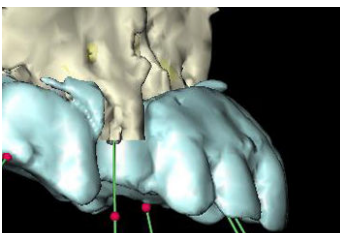
Initial analysis shows an esthetically unsatisfactory appearance. There was a tendency to bite forwards, highlighting the class 3 skeletal appearance. Several teeth were chronically painful and not restorable.



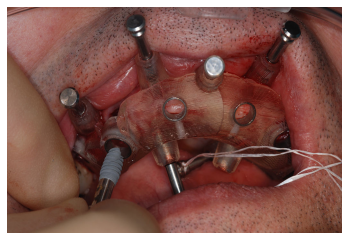
Pre-op radiograph shows optimal amount of bone available in association with failing teeth in the mandible. In the maxilla, a mild bone resorption was seen.



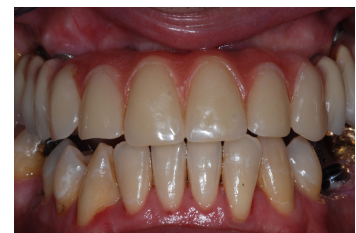NobelClinician used to assess the maxilla for prosthetic-driven implant planning and detailed diagnostics. The digital treatment planning facilitates the correct positioning of the implants according to the new planned appearance.



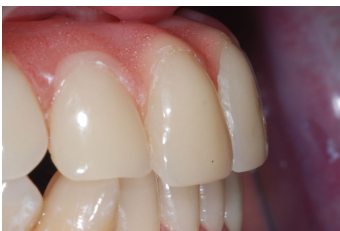The provisional prosthesis has been used in the NobelClinician software to optimize the appearance and then has been used for digital planning of the implant positions.



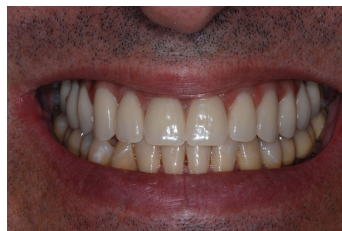The remaining maxillary premolars are removed and the surgical guide is positioned. NobelGuide protocol with a flapless guided surgery takes place for an optimal restorative outcome. The implants are placed immediately into the extraction sockets of the premolars.



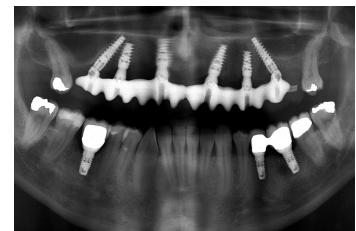
The original removable prosthesis was converted to a simple resin bridge to provide a provisional prosthesis with Immediate Function, fitted on the day of surgery. This was worn for 6 months to allow the remodeling of the bone and to make sure that the patient can adjust to the new occlusal relationship and appearance.



This has been followed by conversion to a precision milled fixed NobelProcera Bridge, allowing a seamless and predictable transition. Support for the upper lip was carefully considered to fulfill the esthetic and functional requirements.



In the maxilla, a NobelProcera Implant Bridge Titanium, veneered in resin was provided. In the mandible, NobelProcera Crowns Zirconia were cemented to individualized NobelProcera Titanium Abutments. The patient is delighted with the improved appearance and has easily adapted to the new occlusal relationship.



Post-op radiograph one year after surgery. This shows good maintenance of bone levels and suggests that the restorations are well seated with the use of the NobelActive implants in the maxilla and the NobelReplace Straight Groovy implants in the mandible.